

# Possible outbreak of skin infections due to Panton-Valentine leukocidin-positive methicillin-resistant *Staphylococcus aureus* on a commercial ship in 2012–2014

**Etienne Bon<sup>1</sup>, Kheira Gadouri<sup>2</sup>, Catherine Avril<sup>3</sup>, Guillaume Camuset<sup>4</sup>, Elsa Balleydier<sup>2</sup>, Isabelle Mathieu<sup>2</sup>, Sandrine Picot<sup>5</sup>, Julien Jaubert<sup>5</sup>, Richard Ballas<sup>1, 6</sup>, Mélanie Colomb-Cotinat<sup>7</sup>, Anne Tristan<sup>8</sup>, Coralie Bouchiat<sup>8</sup>, Laurent Filleul<sup>2</sup>, Frédéric Pagès<sup>2</sup>**

<sup>1</sup>Terres Australes et Antarctiques Françaises (TAAF), Saint-Pierre, Réunion, France

<sup>2</sup>Santé Publique France, French National Public Health Agency, Regional Unit (Cire Océan Indien), Saint-Denis, Réunion, France

<sup>3</sup>Arln FELIN Réunion-Mayotte, Centre Hospitalier Universitaire, Saint-Denis, Réunion, France

<sup>4</sup>Department of Infectious Diseases, Centre Hospitalier Universitaire, Saint-Pierre, Réunion, France

<sup>5</sup>Laboratory of Bacteriology, Centre Hospitalier Universitaire, Saint-Pierre, Réunion, France

<sup>6</sup>Department of Orthopedic Surgery, Centre Hospitalier Gabriel Martin, Saint-Paul, Réunion, France

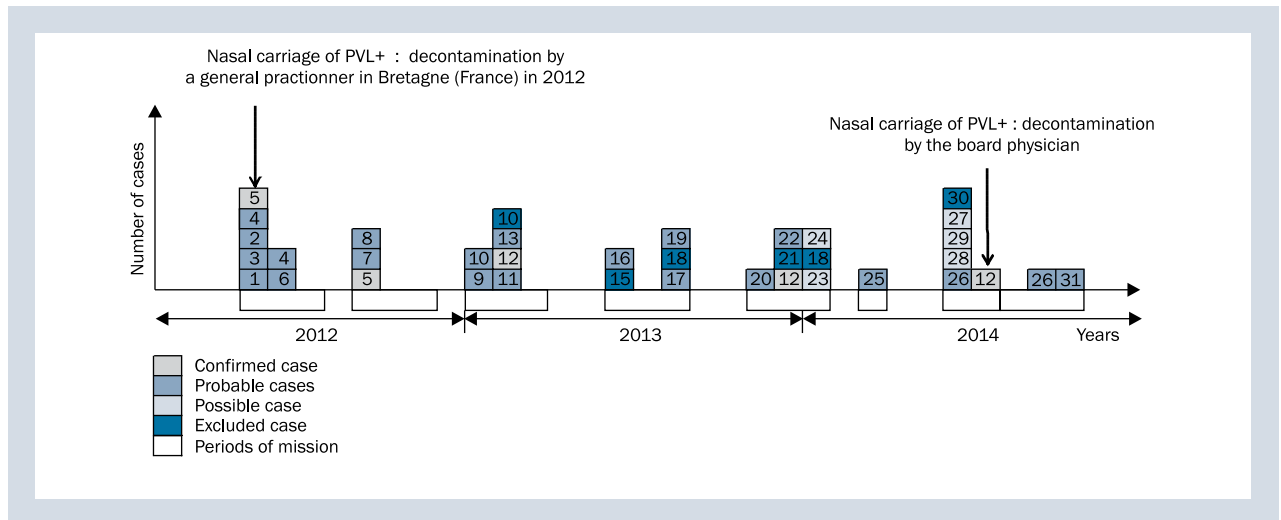
<sup>7</sup>Santé Publique France, French National Public Health Agency, NOA Unit, Saint-Maurice, France

<sup>8</sup>National Reference Centre for Staphylococci, Hospices Civils de Lyon, Bron, France

The emergence of community-associated methicillin-resistant *Staphylococcus aureus* (CA-MRSA) including strains that harbour the Panton-Valentine leukocidin (PVL+) is a challenge for health practitioners especially in high risk communities like sailors [1, 2]. In November 2014, a possible cluster of CA-MRSA skin and soft tissue infections (SSTIs) due to a persistent circulation of a PVL+ strain (CC30-MRSA-IV PVL+ southwest Pacific clone) was signalled on a civilian ship in Reunion Island. First isolated in 2012 colonising a sailor with numerous episodes of SSTIs, this clone was again found in 2014 colonising another sailor. A retrospective analysis of the board medical register showed that SSTIs have occurred regularly during this period but unfortunately no clinical isolates have been collected to confirm a possible outbreak. In February 2015, a field investigation and a screening campaign were organised on board. A form recapitulating the occurrence of suppurative skin lesions during the 3 years was administered to crew members and nasal swabs were collected. Inform consent was obtained from each volunteer. Positive cultures for *Staphylococcus aureus* were sent to the French national reference centre for staphylococci (CNR-staph), Lyon for antimicrobial

susceptibility testing and molecular characterisation [3, 4]. Cutaneous infections cases were then classified in four categories: 1) Possible case: recurrent minimal skin infections (impetigo, folliculitis) without bacteriological sample; 2) Probable case: suppurative primitive skin infections requiring surgical drainage or with spontaneous fistula of a large amount of pus without bacteriological sample (clinical site or colonisation); 3) Confirmed case: probable case with a bacteriological identification of a MRSA (clinical site or colonisation); 4) Other infected skin lesions: sores, herpes, sebaceous cysts, etc. Thirty one patients with one episode or more of infectious skin disease were identified from 2012 to 2014 (Fig. 1). Four patients were excluded. Among the remaining, 2 were considered as confirmed cases, 20 as probable cases and 5 as possible cases representing 54% of crew members. During the interviews, 12 (24%) sailors declared suffering recurrent suppurative skin infections during the study period. Out of the 50 crew members, 47 (94%) agreed to participate in the study. Seventeen (34%) subjects carried methicillin-susceptible *Staphylococcus aureus* (MSSA) without PVL toxin and one was colonised by a MSSA PVL+ belonging to the CC152-MSSA-PVL+ clone. However no





**Figure 1.** Timeline of *Staphylococcus aureus* case-patients (confirmed, probable, possible) and carriers on a commercial ship, Reunion Island, 2012–2014

other colonisation by the CC30-MRSA-IV PVL+ southwest Pacific clone has been found, we cannot rule out that in the past a cluster of SSTIs has occurred due to this clone on board but without bacteriological exploration of the lesions, it is impossible to conclude. In our study, 50% of crew members have presented cutaneous infections clinically compatible with SSTI from 2012 to 2014. To be able to detect a possible outbreak in the future, it was recommended to systematically take a sample of all skin lesions on board and to collect the swabs until the arrival in port. Since 2015, this procedure is used on board and if sporadic infections by MSSA PVL+ or SARM PVL+ have been reported, none outbreak has been identified. Bacteriological documentation of cutaneous infection is essential in high risk communities to rule out the circulation of virulent strains and to implement if necessary specific control measures [5].

## REFERENCES

1. LaMar JE, Carr RB, Zinderman C, et al. Sentinel cases of community-acquired methicillin-resistant *Staphylococcus aureus* onboard a naval ship. *Mil Med.* 2003; 168(2): 135–138, indexed in Pubmed: [12636142](#).
2. Lucas R, Boniface K, Roberts K, et al. Suspected methicillin-resistant *Staphylococcus aureus* infections at sea. *Int Marit Health.* 2007; 58(1-4): 93–102, indexed in Pubmed: [18350979](#).
3. Nhan TX, Bes M, Meugnier H, et al. ST93-Queensland community-acquired methicillin-resistant *Staphylococcus aureus* clone in France: outbreak in a scout camp and sporadic cases, July to August 2012. *Euro Surveill.* 2012; 17(44), indexed in Pubmed: [23137485](#).
4. Monecke S, Slickers P, Ehrlich R. Assignment of *Staphylococcus aureus* isolates to clonal complexes based on microarray analysis and pattern recognition. *FEMS Immunol Med Microbiol.* 2008; 53(2): 237–251, doi: [10.1111/j.1574-695X.2008.00426.x](#), indexed in Pubmed: [18507678](#).
5. Gupta AK, Lyons DCA, Rosen T. New and emerging concepts in managing and preventing community-associated methicillin-resistant *Staphylococcus aureus* infections. *Int J Dermatol.* 2015; 54(11): 1226–1232, doi: [10.1111/ijd.13010](#), indexed in Pubmed: [26228500](#).