



Results of a stemless reverse shoulder prosthesis at more than 58 months mean without loosening

Richard Ballas, MD^{a,*}, Laurent Béguin, MD^b

^aDepartment of Orthopaedic Surgery, University Hospital Center of La Réunion Island, Saint-Pierre, La Réunion, France

^bDepartment of Orthopaedic Surgery, Mutualiste Clinic, Saint-Etienne, France

Hypothesis: A stemless reverse shoulder prosthesis with humeral cup was developed to allow stemless press-fit fixation, to preserve bone stock. Our hypothesis was that a stemless reverse shoulder arthroplasty could produce the same functional results without compromising humeral fixation.

Methods: This is a continuous, prospective, single-surgeon series including prostheses implanted from 2004 to 2009. Patients received pre- and postoperative clinical evaluation with measurement of joint mobility, the Oxford Shoulder score, and the Constant-Murley score by independent evaluators. Standard radiographs and computed tomographic arthrography were performed.

Results: Fifty-six implants were reviewed at a mean of 58 months (38-95). The Constant-Murley score improved from 29 to 62 points and the Oxford Shoulder score from 46 to 17 points. Active elevation in forward flexion improved from 79° to 140°. One intraoperative complication was recorded: a metaphyseal-diaphyseal humeral bone crack without consequence. One revision surgery due to early instability was performed using a conventional implant. No humeral loosening was observed. Five cases of scapular notching were reported.

Conclusion: This is the first study reporting results with mid-term follow-up for a stemless reverse shoulder arthroplasty. The clinical results are comparable to conventional prostheses with stem. The absence of a humeral stem preserves bone stock for possible later revisions.

Level of evidence: Level IV, Cases Series, Treatment Study.

© 2013 Journal of Shoulder and Elbow Surgery Board of Trustees.

Keywords: Shoulder arthroplasty; reverse shoulder arthroplasty; stemless prosthesis

The advantages of stemless prosthetic implants are well known in orthopedic surgery: fewer intraoperative iatrogenic problems and complications, and fewer postoperative problems and complications. Authors have reported intraoperative complications (false route, malposition, metaphyseal-diaphyseal fracture of the humerus)¹³ and postoperative complications (disassembly, peri-prosthetic fracture, stem fracture, loosening,

migration)^{9,11,13} related to insertion of a stemmed prosthesis. In cases of malunion, obstruction of the humeral diaphysis or a long-stem elbow prosthesis, it is sometimes not possible to implant a humeral stem. When revision of a stemmed implant is necessary, the removal of the implant is more difficult and may result in additional iatrogenic complication due to bone damage generated.¹³

A stemless implant with metaphyseal fixation was developed to allow a press-fit fixation without stem, to preserve bone stock. This implant resulted in fewer constraints due to the medullary axis or remodeled anatomy. The humeral implant could be implanted automatically centered by

*Reprint requests: Richard Ballas, MD, Department of Orthopaedic Surgery, University Hospital Center of La Réunion Island, Hospital of Saint-Pierre, BP 350, 97 448 Saint-Pierre Cedex, La Réunion Island, France.

E-mail address: richardballas@yahoo.fr (R. Ballas).

obviating the medial and posterior offset induced by the axis of the humeral shaft. A stemless prosthesis is an alternative to standard reverse stemmed prosthesis, with the advantage of less invasive surgery, fewer stem complications and the possibility of easier revisions.

Stemless shoulder prostheses emerged during the early 2000s. Anatomic implants without stems have proven to provide secure primary radiological fixation and good clinical outcomes.^{6,7} The position of stemmed anatomical prostheses may be less than perfect despite modularity due to unique individual anatomy. The use of stemless anatomical prostheses may be of interest due to differing humeral canal orientations. Despite the good results obtained with the use of stemless anatomical implants, the use of stemless reverse prostheses was limited for fear of failure of bone fixation, due to greater forces on the implant.

Our hypothesis was that a stemless reverse shoulder arthroplasty may avoid complications related to the humeral stem, without affecting the fixation of the humeral component and functional results. The aim of our study was to evaluate the functional results and bone stability of the humeral component of a new stemless reverse shoulder arthroplasty.

Materials and methods

Population

We prospectively enrolled all stemless reverse shoulder prostheses implanted from 2004 to 2009 with a minimum follow-up of 36 month. This represented 56 patients. We excluded cases of stemmed prosthesis (15) which were implanted in case of revision and acute proximal humeral fracture. This was a continuous single surgeon series. The TESS (Total Evolutive Shoulder System) prosthesis (Biomet Inc, Warsaw, IN, USA) was the only reverse prosthesis in use during this period.

Description of the implant and surgical technique

The humeral stemless cup is made of cobalt-chrome with a titanium plasma spray and hydroxyapatite coating, impacted into the humeral metaphysis. The polyethylene is clipped inside the cup and held by a metal ring. The surface of the corolla is composed of 6 anti-rotational wings (Figs. 1 and 2). The glenosphere is made of cobalt-chrome and is bolted to a glenoid baseplate fixed by 4 screws.

The surgical procedure was performed under general anesthesia and patients received an inter-scalene block. The procedure was performed in a “beach chair” position using a deltopectoral approach. The subscapularis muscle was incised vertically in the upper third of the tendon. A cutting guide stem was introduced along the axis of the humeral shaft and a metaphyseal bone cut was performed with the help of a 150° tilt guide. A pin was centered on the bone resection using a template and a humeral reamer was centered on the resected humeral cut. The pin was removed and a guard was placed on the cut surface during the glenoid preparation time. The glenoid baseplate was inserted and fixed by screws and the glenosphere was impacted and screwed onto the baseplate. A specifically selected diameter hole was then drilled into the humerus in order to create a metaphyseal box which could receive the final



Figure 1 Lateral view of the humeral stemless cup.



Figure 2 Posterior view of the humeral stemless cup.

corolla to allow for press-fit impaction. Trial humeral inserts were tested and the final polyethylene insert was impacted. After testing the amplitude and stability, the subscapularis muscle was reattached to the lesser tuberosity. Drains were inserted and removed at two days. In the postoperative period, patients were immobilized by a brace in abduction at 30° for 45 days and rehabilitation care was immediate (Fig. 3). Rehabilitation by a physiotherapist was started with passive and active mobilization above the plane of the orthosis. External rotation was limited to the neutral position for the first 6 weeks to protect the subscapularis muscle reinserted.

Method of assessment and statistics

General and administrative data was collected preoperatively. Patients were seen in consultation for a clinical and radiological

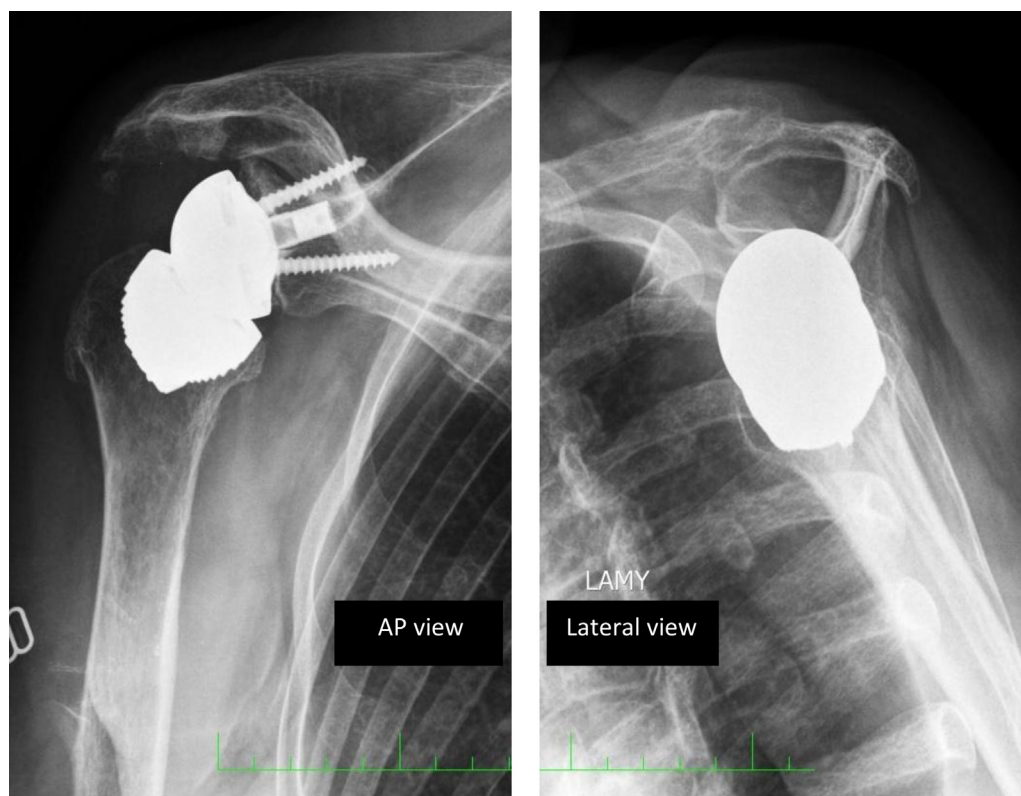


Figure 3 Standard postoperative x-rays of reverse shoulder prosthesis without stem.

assessment at 45 days after surgery, 3 months, 6 months, 1 year, and annually thereafter. All patients were clinically assessed by measuring range of motion using a goniometer, and evaluated using the Oxford shoulder score.³ The Constant-Murley score² was administered by independent reviewers.

Radiological examination included standard radiographs in three planes, and a Lamy profile view. Computed tomographic (CT) arthrography was performed before surgery to assess the status of the rotator cuff. The radiographs were evaluated by the 2 authors, both orthopaedic surgeons, in order to discern any migration of the implant, secondary displacement, the appearance of radiolucent lines, osteolysis, or signs of loosening compared to previous films and postoperative ones.

We grouped the shoulders using the Hamada-Fukuda classification for cuff tear arthropathy.⁵ During surgical exploration, the status of the rotator cuff was evaluated and noted. Intraoperative complications (humeral fractures, glenoid fractures) and postoperative complications (hematoma, infection, and neurological disorder) were identified.

Statistical analysis was performed using SPSS software (version 17.0; SPSS Inc., Chicago, IL, USA) for averages and percentages. The normality of distribution for quantitative values was assessed using the skewness and kurtosis coefficients and the Kolmogorov-Smirnov (Lilliefors) test. The parametric Student *t*-test for paired samples was used to compare the pre-operative and post-operative values. Statistical significance was set at $P \leq .05$ for all tests.

Results

Fifty-six TESS reversed prostheses without stems were implanted in 56 patients (16 men, 40 women). The mean

follow-up was 59 ± 14 months (38-95, median = 57). The average age at the time of operation was 74 ± 7 years (55-85). Three patients (3 shoulders) were lost to follow-up. The dominant side was involved in 39 cases. The etiologies were as follows: 36% (20 shoulders) massive rotator cuff tears, 59% (33) cuff tear arthropathy, and 5% (3) primary osteoarthritis. The mean body mass index was 26 ± 4 kg/m² ([18-36] including 10 obese patients). The pre- and post-operative data of patients and Oxford and Constant-Murley scores were as noted in Table I.

Preoperative radiographs were used to classify 46 shoulders (82%) as Hamada and Fukuda I, II, or III scores and 10 shoulders (18%) were stage IV or V. The assessment of the cuff status and fatty degeneration was reported in Table II.

We had several complications. One minor intraoperative complication occurred on the humeral side during the 16th procedure. It was an intraoperative partial humeral metaphyseal crack confirmed by postoperative x-ray. Primary stability was correct and there was no secondary displacement of the implant. Postoperative rehabilitation was the same than other patient.

In the postoperative period, we identified a case of superficial infection which was treated conservatively. One patient receiving anti-vitamin K required a surgical evacuation of a hematoma on the 21st day. One rupture of the subscapularis was found at the 1-year postoperative visit. A stress fracture of the acromion occurred 4 years after surgery and was treated conservatively.

Table I Preoperative and postoperative data and gain: average (minimum-maximum ; standard deviation)

	Preoperative	Postoperative	Gain	P
Constant (/100)	29 (16-59; ± 8)	62 (38-85; ± 12)	+33	<.001
Pain (/15)	5 (0-13; ± 3)	12 (5-15; ± 3)	+8	<.001
Activity (/20)	8 (3-16; ± 3)	17 (9-20; ± 3)	+9	<.001
Mobility (/40)	14 (2-34; ± 5)	26 (14-36; ± 6)	+12	<.001
Strength (/25)	2 (0-4; ± 1)	6 (0-16; ± 4)	+4	<.001
Oxford (/60)	46 (34-65; ± 5)	17 (12-30; ± 4)	-29	<.001
Function (/40)	31(23-37; ± 4)	12 (8-22; ± 4)	-19	<.001
Pain (/20)	15 (8-40; ± 4)	5 (4-9; ± 1)	-10	<.001
Anterior active elevation	79° (20-150; ± 28)	140° (90-170; ± 17)	+61°	<.001
External rotation	13° (-40-70; ± 22)	45° (0-70; ± 15)	+32°	<.001

Table II Pre- and postoperative assessment of the rotator cuff

	CT scan	Intraoperative assessment
Number of tendons tear (subscapularis, supraspinatus, infraspinatus)		
0	0%	0%
1	8%	11%
2	47%	45%
3	45%	44%
Supraspinatus tear	100%	99%
Infraspinatus tear	88%	85%
Subscapularis tear	34%	34%
Long portion biceps tear	87%	87%
Fatty degeneration		
1	1%	
2	19%	
3	75%	
4	5%	

At the latest follow-up, there were no peri-prosthetic humeral radiolucencies, migration, or loosening of the reverse humeral cup in the metaphysis. No modification of the outcrop of the corolla over the cut surface bone appeared. In 1 case, significant lysis of the greater tuberosity was noted, without secondary displacement of the humeral corolla. Five stage 1 scapular notches appeared (9% of cases), 1 was observed 6 months after the procedure and four 12 months after the procedure.

Revision surgery was necessary in 4 cases (7%). Dissociation of the glenoid components occurred three times. Revision surgery was possible with a reverse prosthesis with primary stems in 2 cases (1 case with iliac graft of the glenoid). A simple implant removal was performed in a third patient whose health status was poor. One patient had an episode of instability 3 days after the procedure, when passive external reduction caused a displacement of the humeral corolla, which required further surgery. This was revised to a stemmed implant from the same manufacturer.

Discussion

This is the first study reporting specifically the results of a stemless reverse shoulder arthroplasty. There was no loosening of the humeral implant at a mean of 58 months follow-up. Epidemiologic, etiological, and radiographic data of the patients in our series were similar to those of patients in the literature.⁵ The improvement in Constant score (33 points) and its components (pain: 8 points, activity: 9, mobility 12 points and strength 4 points) were comparable to the scores of a French multicenter study in 2006¹ (Constant: +38 points). The mean preoperative elevation of 79° improved to 140° postoperatively (increase of 61°) which corresponds to literature data^{1,12} (59° for the French multicenter study symposium series).

The results of stemless anatomic total shoulder arthroplasty were recently evaluated and showed functional results comparable to stemmed prostheses, with excellent bone fixation^{6,7} without the appearance of radiolucent lines or loosening. The use of stemless reverse shoulder arthroplasty required an evaluation of humeral stability, as the joint constraint leads to increased forces at the bone interfaces. Our study showed that at almost mean 5-year follow-up, bony stability was not compromised. Only 1 traumatic case occurred on the third postoperative day, as noted above. Radiographic analysis showed no periprosthetic radiolucent lines or signs of loosening at the last follow-up. There was no radiographic evidence of implant migration.

The advantages of implants without stem are known in orthopedic surgery—potentially fewer intra-operative iatrogenic complications and post-operative complications. Two large series have reported complications of reversed shoulder prostheses.^{4,13} Complications related to the humeral stem accounted for 10¹-20%¹³ of postoperative complications, including periprosthetic fracture, disassembly, and loosening. The prevalence was 4.2%, representing 20% of postoperative complications.¹³ Baulot et al's analysis in the French multicenter study showed that 10% of reversed shoulder prostheses complications were related to the humerus, with a prevalence of 2.1% for humeral complications and 1.5% for peri-prosthetic fractures.¹ Zumstein et al showed that it is difficult

to collect the data, as the revision rates are variable due to unclear definitions of complications and revisions.¹³

The implantation of an intramedullary stem, however, has risk. When revision was needed, removal of the stem can be difficult. Zumstein et al reported 16 intraoperative humeral fractures and 24 intraoperative complications (67%) related to the humeral stem, which occurred mainly during removal of the primary humeral stem or cement mantle in 24.1% of revision surgery.¹³ Another advantage of a stemless prosthesis is preservation of bone stock, so that revision surgery can be performed more easily and safely. We also noted, on a subjective level, fewer complaints of arm pain with the stemless reverse prosthesis compared to our stemmed implants.

The positioning of the humeral corolla, as to its inclination and version, was independent of humeral shaft orientation. The rate of scapular notching was 9%, all of stage I. These notches appeared 1 year after surgery (except in 1 case) and were nonprogressive at last follow-up. Kadum et al⁸ did not report notches in the 21 TESS reversed prostheses (Biomet Inc) included in his study at a mean of 14 months. The prevalence of notches in the literature varies widely and can exceed 50%.⁴ The French multicenter study reported a notch in 68% of cases at a mean 51 months.¹ The notches seemed to appear early, with 48% occurring at 1 year follow-up and 60% at 2 year follow-up. Their progression and significance were difficult to interpret.

Revision surgeries in our study were related to glenoid disassembly in 3 cases and 1 case of an early traumatic displacement of the humeral corolla, caused by external manipulation of reduction of a postoperative dislocation. Surgical revision was performed using a primary implant with stem. The surgical procedure took place without any particular difficulty with the preservation of bone stock from its initial cut. The original implant could be extracted without degradation of the remaining bone stock and the humeral component was implanted in the same orientation as a primary stemmed reverse shoulder prosthesis.

The rate of glenoid complications (5%) was comparable to those reported in the literature (5.1% in the French multicenter study¹⁰ with 4.1% loosening and 5.75% reported by Farshad and Gerber⁴). The design of the glenoid socket and its attachment were improved after this series of implants. The initial glenoid component had an impaction system between the baseplate and glenosphere which was difficult to implant, which led, in some cases, to incomplete attachment and dissociation, which was why 3 revisions were necessary to change the glenoid component. The design improvement concerned the Morse taper, and the bony fixation of the baseplate was modified to allow better bone anchorage with screws and pins.

Indications for surgery were the same as for stemmed implants. The contraindications concerned cases of advanced osteopenia with metaphyseal cancellous bone or uncertain quality. In the early stages of our study, we preferred to use a stemmed implant for some cases when we had concerns about fixation (15 during the period of this series), which is

a limitation of this study. However, after this series, we have exclusively used stemless reverse prostheses.

We included patients after a minimum of 36 months of follow-up, which is enough time to observe any humeral implant migration on radiographs. The follow-up in our series (58 months; range, 38-95) was comparable to the overall follow-up of the French multicenter study (54 months; range, 2-17 years).¹

Conclusion

This was the first specific study reporting the results of a stemless reverse prosthesis. Clinical and radiological outcomes at almost 5-year follow-up were comparable to stemmed reverse shoulder prostheses. We did not have complications related to the stem, as described in the literature, and the stemmed implant were indicated for easier revision surgery. Our study showed the possibility of safely implanting a stemless humeral cup for reverse shoulder arthroplasty. It now appears reasonable to consider a stemless humeral implant for a primary reverse shoulder prosthesis. Studies are needed to assess the longer-term outcome of this new type of implant.

Disclaimer

Dr Béguin received royalties and consultant payments from Biomet Compagny, Warsaw, Indiana, which is related to the subject of this work. The other author, their immediate families, and any research foundations with which they are affiliated have not received any financial payments or other benefits from any commercial entity related to the subject of this article.

References

1. Baulot E, Valenti P, Garaud P, Boileau P, Neyton L, Sirveaux F, et al. Résultats des prothèses inversées. *Revue de Chirurgie Orthopédique et Réparatrice de l'Appareil Moteur* 2007;93(Suppl 1):63-92. [http://dx.doi.org/10.1016/S0035-1040\(07\)92712-9](http://dx.doi.org/10.1016/S0035-1040(07)92712-9)
2. Conboy VB, Morris RW, Kiss J, Carr AJ. An evaluation of the Constant-Murley shoulder assessment. *J Bone Joint Surg Br* 1996 Mar; 78:229-32.
3. Dawson J, Fitzpatrick R, Carr A. Questionnaire on the perceptions of patients about shoulder surgery. *J Bone Joint Surg Br* 1996;78:593-600.
4. Farshad M, Gerber C. Reverse total shoulder arthroplasty-from the most to the least common complication. *Int Orthop* 2010;34:1075-82. <http://dx.doi.org/10.1007/s00264-010-1125-2>
5. Favard L, Gerber C, Berhouet J, Bacle G, Nérot C, Garaud P, et al. Introduction, démembrément et présentation de la série. *Revue de Chirurgie Orthopédique et Réparatrice de l'Appareil Moteur* 2007; 93(Suppl 1):40-50. [http://dx.doi.org/10.1016/S0035-1040\(07\)92709-9](http://dx.doi.org/10.1016/S0035-1040(07)92709-9)
6. Geurts GF, Van Riet RP, Jansen N, Declercq G. Placement of the stemless humeral component in the Total Evolutive Shoulder System

- (TESS). *Tech Hand Up Extrem Surg* 2010;14:214-7. <http://dx.doi.org/10.1097/BTH.0b013e3181e397c5>
7. Huguët D, DeClercq G, Rio B, Teissier J, Zipoli B. Results of a new stemless shoulder prosthesis: radiologic proof of maintained fixation and stability after a minimum of three years' follow-up. *J Shoulder Elbow Surg* 2010;19:847-52. <http://dx.doi.org/10.1016/j.jse.2009.12.009>
 8. Kadum B, Mafi N, Norberg S, Sayed-Noor AS. Results of the Total Evolutive Shoulder System (TESS®): a single-centre study of 56 consecutive patients. *Arch Orthop Trauma Surg* 2011;131:1623-9. <http://dx.doi.org/10.1007/s00402-011-1368-4>
 9. Levy O, Copeland SA. Cementless surface replacement arthroplasty (Copeland CSRA) for osteoarthritis of the shoulder. *J Shoulder Elbow Surg* 2004;13:266-71. <http://dx.doi.org/10.1016/S1058274604000229>
 10. Molé D, Favard L. Omarthrose ecentrée. *Revue de Chirurgie Orthopédique et Réparatrice de l'Appareil Moteur* 2007;93(Suppl 1):37-9. [http://dx.doi.org/10.1016/S0035-1040\(07\)92708-7](http://dx.doi.org/10.1016/S0035-1040(07)92708-7)
 11. Wirth MA, Rockwood CA Jr. Complications of total shoulder-replacement arthroplasty. *J Bone Joint Surg Am* 1996;78:603-16.
 12. Young SW, Everts NM, Ball CM, Astley TM, Poon PC. The SMR reverse shoulder prosthesis in the treatment of cuff-deficient shoulder conditions. *J Shoulder Elbow Surg* 2009;18:622-6. <http://dx.doi.org/10.1016/j.jse.2009.01.017>
 13. Zumstein MA, Pinedo M, Old J, Boileau P. Problems, complications, reoperations, and revisions in reverse total shoulder arthroplasty: a systematic review. *J Shoulder Elbow Surg* 2011;20:146-57. <http://dx.doi.org/10.1016/j.jse.2010.08.001>